

# Chest Trauma, Injury 2006, Auckland

1. Resuscitation
2. Diagnosis - juxtacardiac
3. The Blunt Arch
4. The Wandering bullet



# Emergency & Resuscitative Thoracotomy

- D/C Status: Of 15 survivors:
- 11 to home w/o support GCS of 15
- 2 D/C home with some support, 2 to another care facility (one with GCS 9 died 3 Mo. Later)





# Emergency & Resuscitative Thoracotomy

- In Blunt Trauma:  
All survivors had + BP in ER & All successful thoracotomies were performed in OR.
- In Penetrating Trauma:  
Survivors from all groups.  
36% of survivor thoracotomies were performed in ER
- 1/3 of ED thoracotomies performed for penetrating trauma survived.
- Our findings support the recommendations of the American College of Surgeons Committee on Trauma





# Factors Affecting Prognosis with Penetrating Wounds of the Heart

James G. Tyburski, MD, Louis Astra, MD, Robert F. Wilson, MD, Christopher Dente, MD, and Christopher Steffes, MD

**Objective:** To determine factors affecting prognosis for patients with penetrating wounds of the heart.

**Methods:** A retrospective review of 302 patients with penetrating heart wounds undergoing emergency thoracotomy (August of 1980 through June of 1997) in a Level I trauma center.

**Results:** There were 148 patients with gunshot wounds (GSW) and 154 patients with stab wounds with 23% and 58% survival rates, respectively. Of 43 patients having no signs of life at the scene, 5 patients (12%) achieved some cardiac activity and were brought to the operating room (OR), but none survived. Of 67 patients "arresting" in the ambulance, 23 got to the OR, but only 3 patients (4%) survived. Of 27 patients "arresting" in the emergency department (ED), 18 patients reached the OR, but only 5 patients (19%) survived. Of 15 patients having an ED thoracotomy because of rapid deterioration there, 4 patients (27%) survived. Thus, of the 152 patients with an ED thoracotomy, 93 patients had gunshot wounds and none survived; of the

59 with stab wounds, 12 (20%) survived ( $p < 0.001$ ). Of 150 patients having an OR thoracotomy, 111 (74%) survived. Single-chamber injuries had a survival rate of 51% (112 of 219 patients), but multiple chamber and/or intrapericardial great vessel injuries had only a 13% survival rate (11 of 83 patients) ( $p < 0.001$ ). Intrapericardial aortic injuries were uniformly fatal in 15 patients. In patients with stab wounds, pericardial tamponade was associated with a higher survival rate (66%; 56 of 84 patients) than in those without tamponade (47%; 33 of 70 patients).

**Conclusion:** The physiologic status of the patient at presentation, mechanism of injury, and presence of a tamponade were significant prognostic factors in this series of penetrating cardiac injuries. Multiple-chamber injuries, especially with great vessel involvement, were associated with a high mortality rate. ED thoracotomies for gunshot wounds of the heart were uniformly fatal.

0022-5282/00/4804-0587

The Journal of Trauma: Injury, Infection, and Critical Care  
Copyright © 2000 by Lippincott Williams & Wilkins, Inc.

Vol. 48, No. 4  
Printed in the U.S.A.





# Tyburski et al, J Trauma 2000

- Detroit receiving, Penetrating heart wounds. 17 years 152 ED thoracotomies & 150 OR thoracotomies.
- OR Thoracotomies 74% survival
- Of The 152 ED thoracotomies
  - 93 GSW no survivors
  - 59 stab wounds - 20% survivors.






# Emergency & Resuscitative Thoracotomy

1. If signs of life are present, or were present during transport, and the trauma is penetrating, the thoracotomy is justified. If the cause is cardiac tamponade, the prognosis is even better.
2. If blunt trauma is present, the chance for survival is limited. Hence, it is justified when signs of life are present at the moment of starting the thoracotomy. If airway management does not improve the patient's condition, the thoracotomy is not justified.
3. If after opening the pericardium no evidence of cardiac activity is found; the next step is clamping the aorta and providing fluid infusion. In these cases, unless cardiac injury is found, the prognosis is poor. Cardiac arrest due to hypovolemia is not reversible until fluids are administered.<sup>107,108</sup>
4. If after aortic occlusion the systolic blood pressure does not reach at least 70 mm Hg after 30 minutes, the patient must be considered dead and the thoracotomy must be ended.



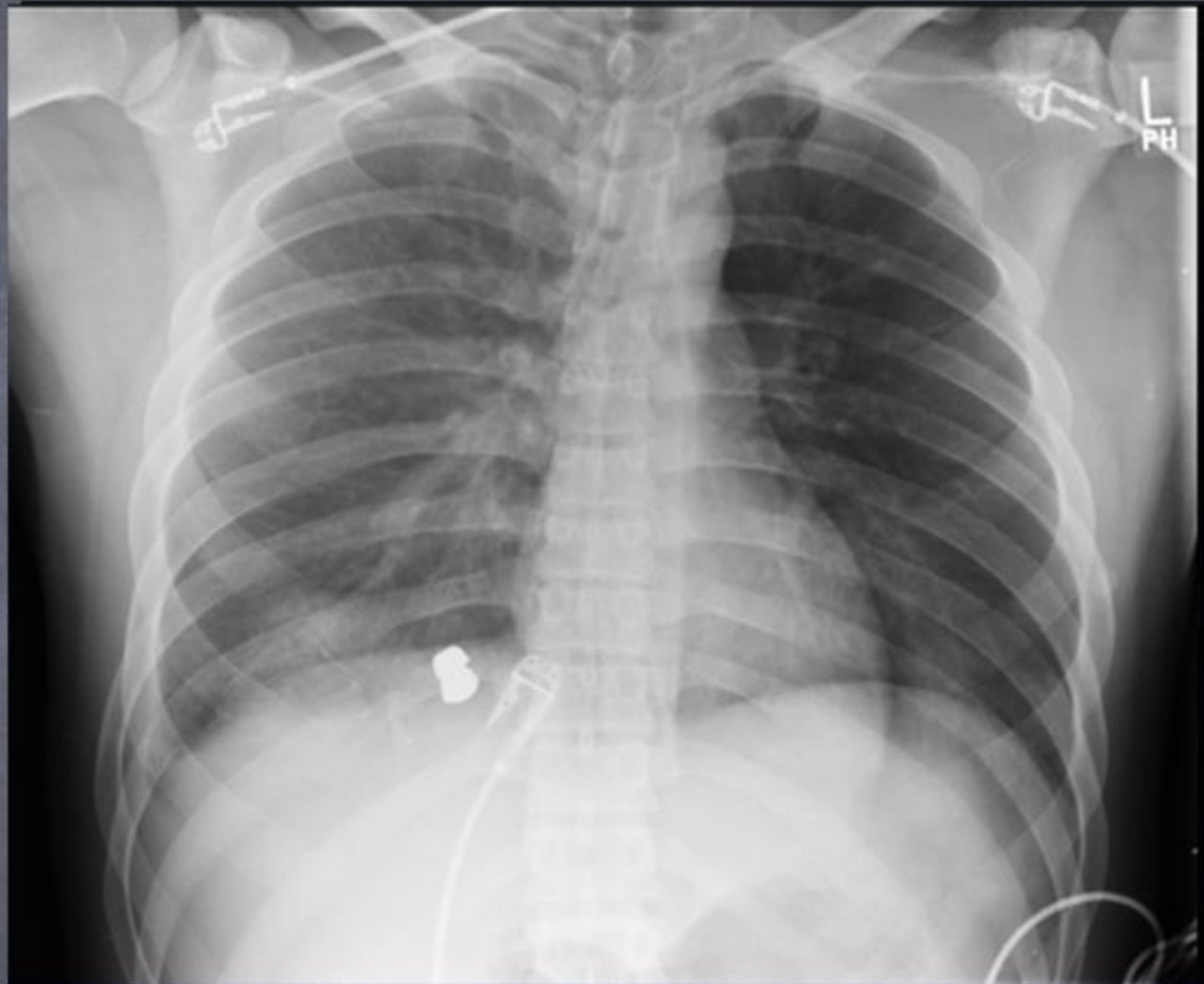




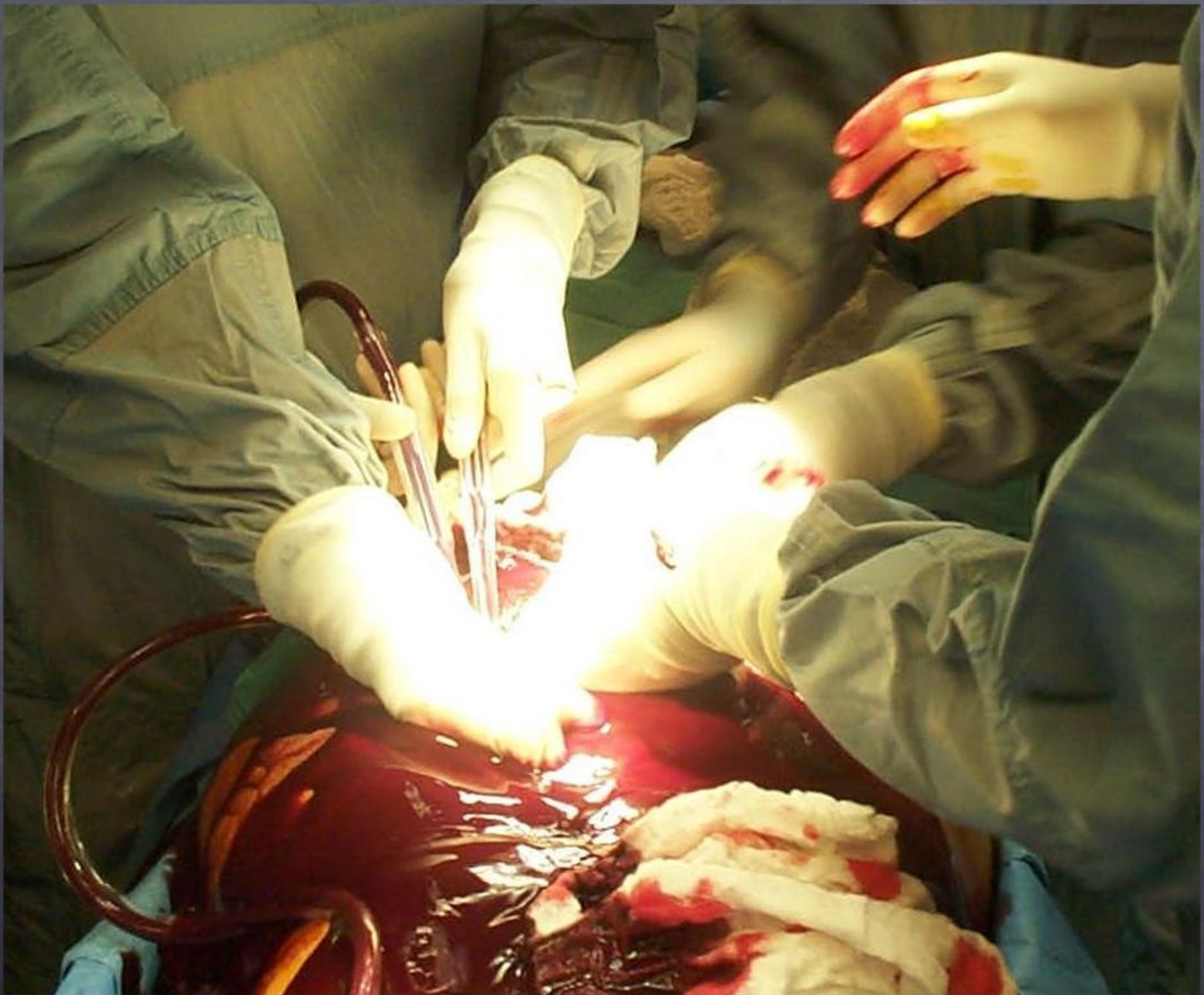
John B Kortbeek MD FRCS FACS, Departments of Surgery & Critical Care, University of Calgary



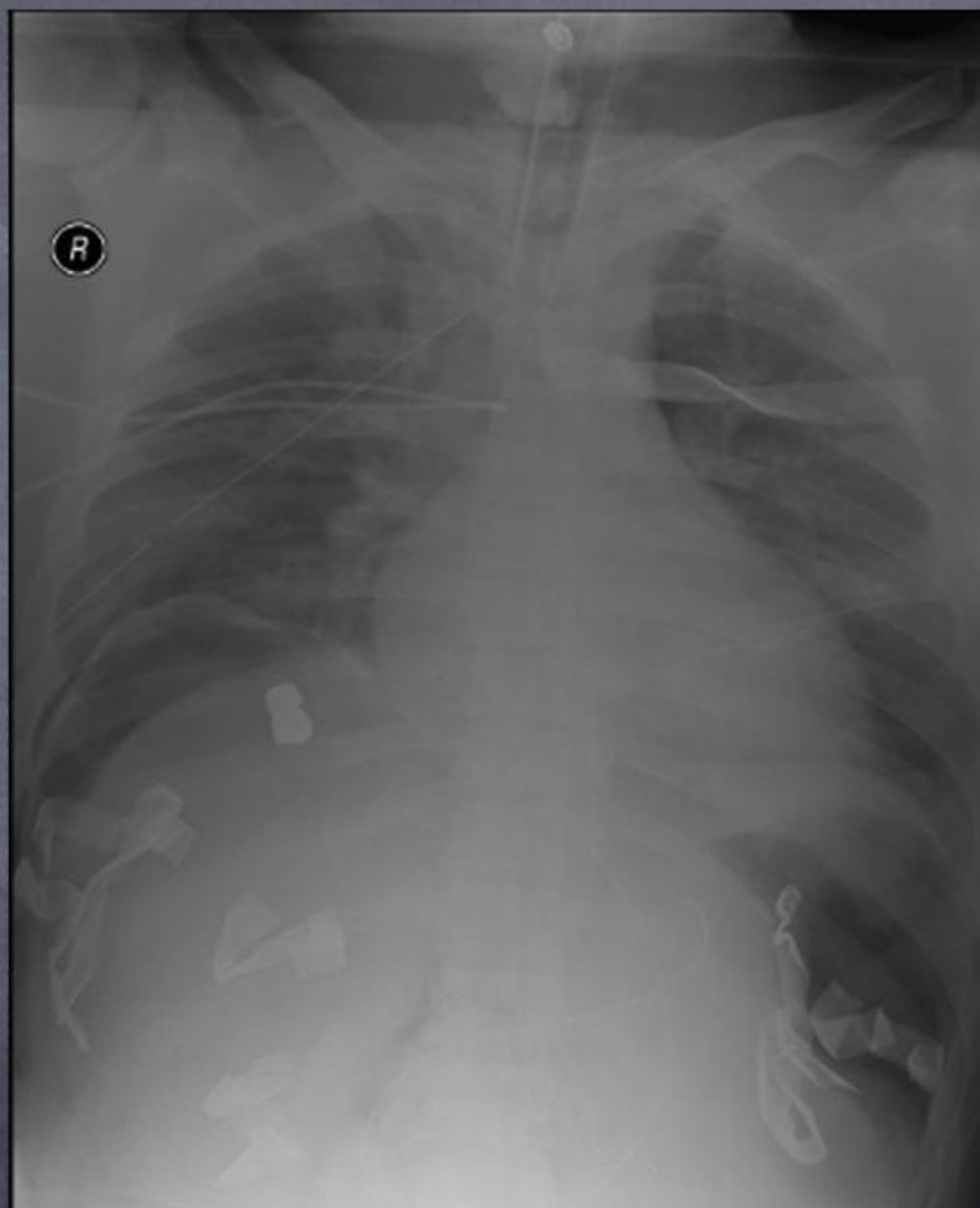




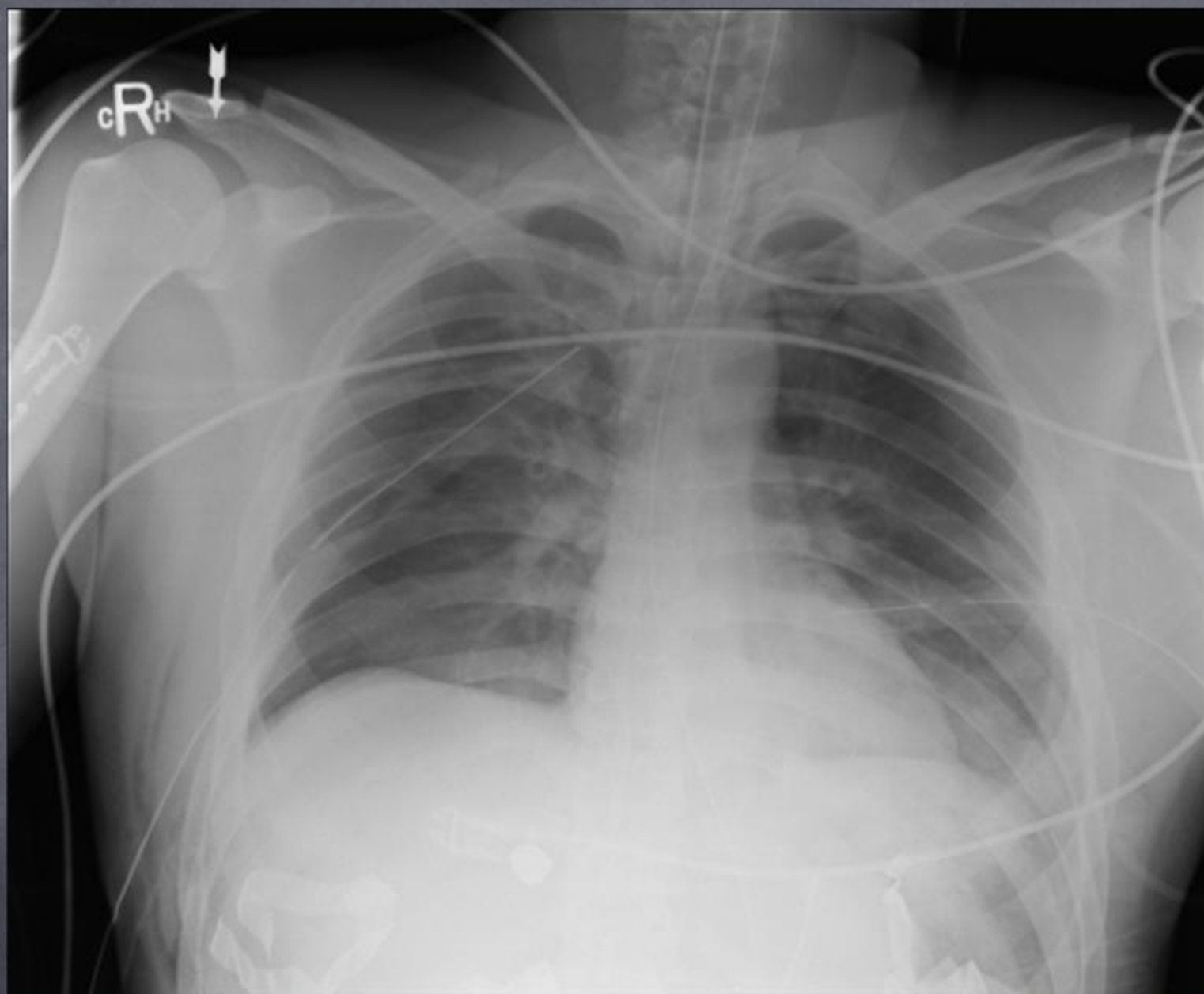












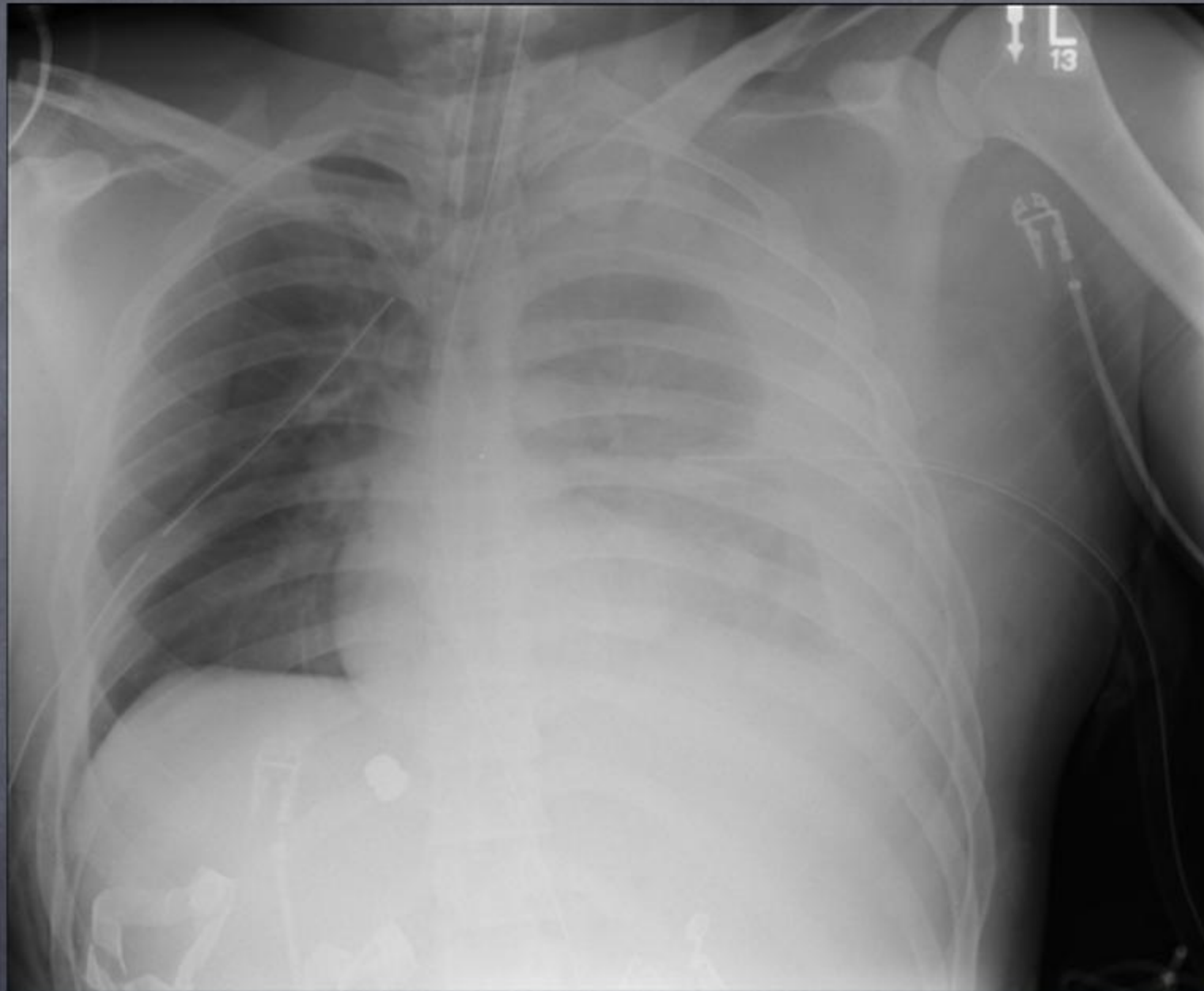


# Emergency & Resuscitative Thoracotomy

- To evaluate the survival of Adult Trauma Patients in the Calgary Health Region who have undergone Emergency Thoracotomy.
- To evaluate further outcomes of the survivors.
- To document variation in technique used for emergency thoracotomies in the region.

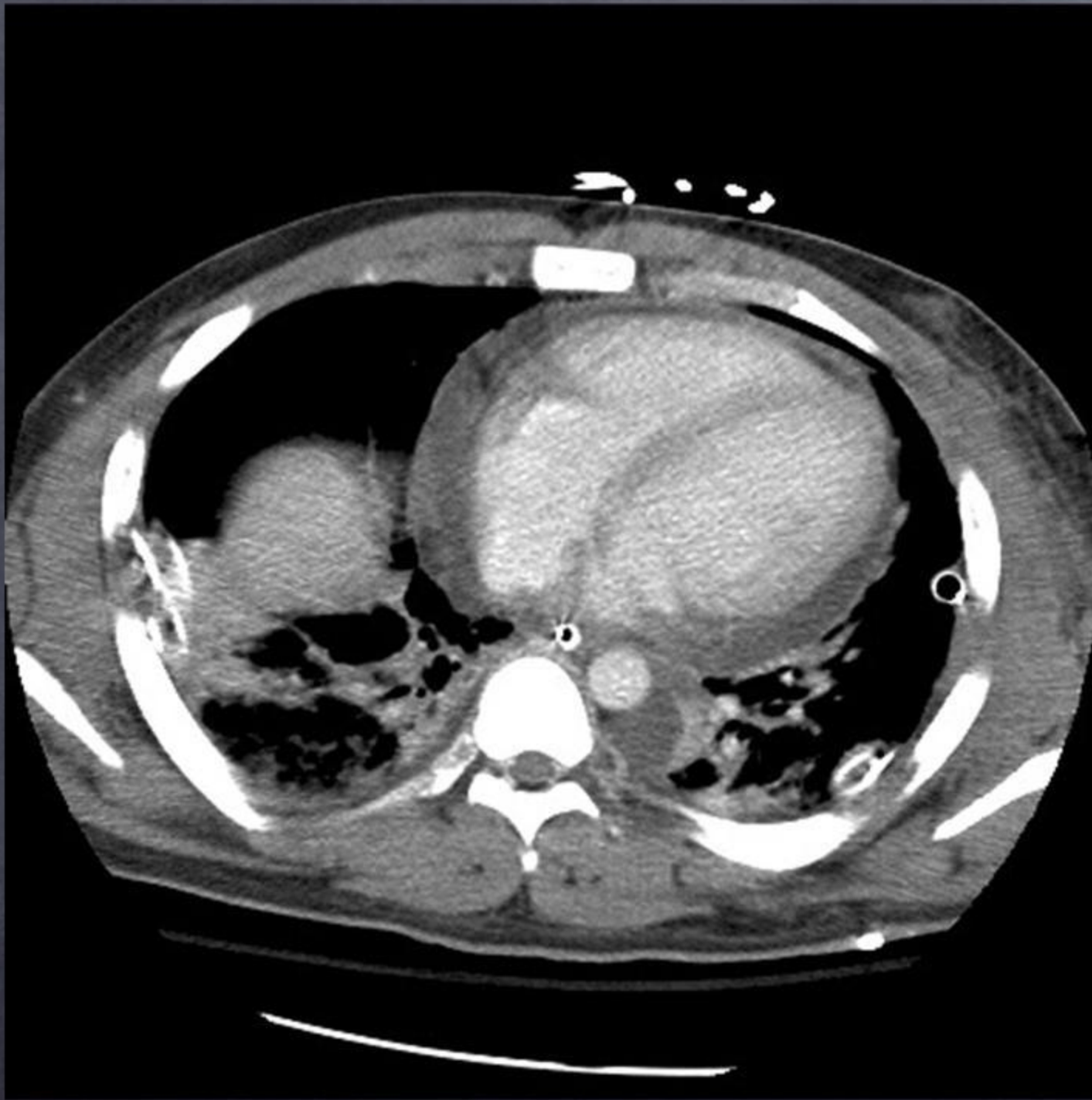








## Approach to juxtacardiac wounds





# Juxta-cardiac wounds

- 1. Pericardial window
- 2. Echo TTE, TEE
- 3. FAST
- 4. CT
- 5. Local exploration



# FAST

- Acad Emerg Med 2000, Wisconsin
- Residents and faculty - Emergency Med Training program exposed to standard subxiphoid FAST exams and questionnaires
- Sensitivity 73%, specificity 44%
- Epicardial fat pads confused with effusions.



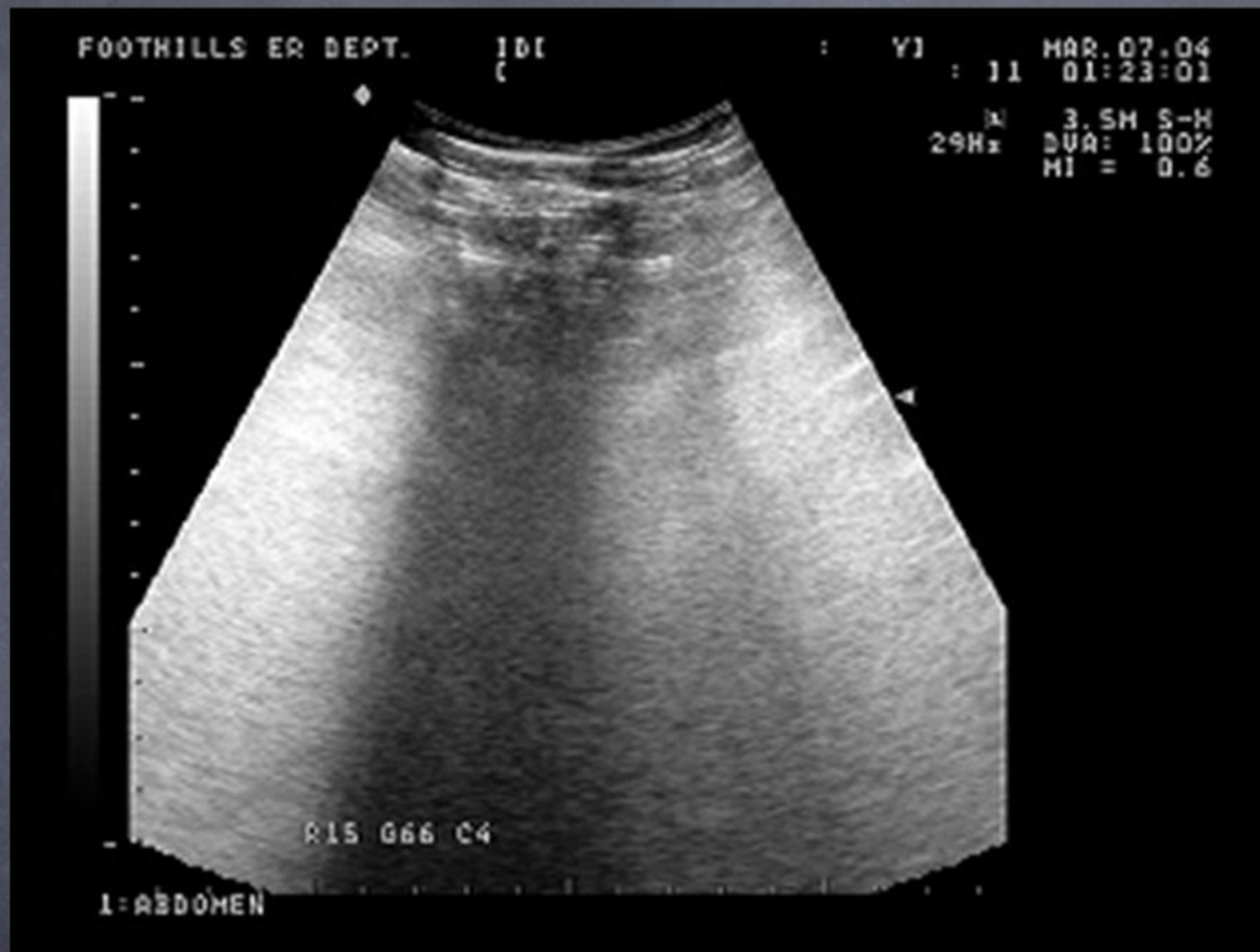


# FAST

- Annals Thor Surg 2003, Baylor
- 478 patients underwent sonography for penetrating thoracic trauma
- 23 positive, 20 had a cardiac injury at surgery. Spec 99% PPV 87% NPV 100%









# Reevaluation of Diagnostic Procedures for Transmediastinal Gunshot Wounds

*Nicole A. Stassen, MD, James K. Lukan, MD, David A. Spain, MD, Frank B. Miller, MD, Eddy H. Carrillo, MD, and J. David Richardson, MD*

- **CT:** Louisville, Kentucky, 22 stable transmediastinal GSW, CXR, U/S negative
- 7 positive - further investigation led to thoracotomy in 2.
- 15 negative, no further investigations, therapy required.
- CT safe and effective for evaluation of stable transmediastinal GSW





# Juxtacardiac wounds

- Stab Unstable with vitals, GSW below nipples.( Stable or unstable with vitals) - CXR then to OR.
- Nipples and below - Lap first. Above nipples thoracotomy first.
- Stable stab or GSW above nipples - CXR - FAST - If negative then to CT, if positive then to OR for window or thoracotomy.
- Ant. Stab - sternotomy, GSW - Ant Lat thoracotomy.









# Challenging Paradigms Blunt Aortic Injury.

- Endovascular repair
- Timing



# Emergency & Resuscitative Thoracotomy

- 5 year retrospective study.
- Prehospital and hospital records were reviewed for all trauma patients requiring emergency thoracotomies who were brought to Foothills Hospital, a Level I Trauma Center, during a 5-year period (Apr 1998 - Mar 2003).
- Patients were identified through the Alberta Trauma Registry.

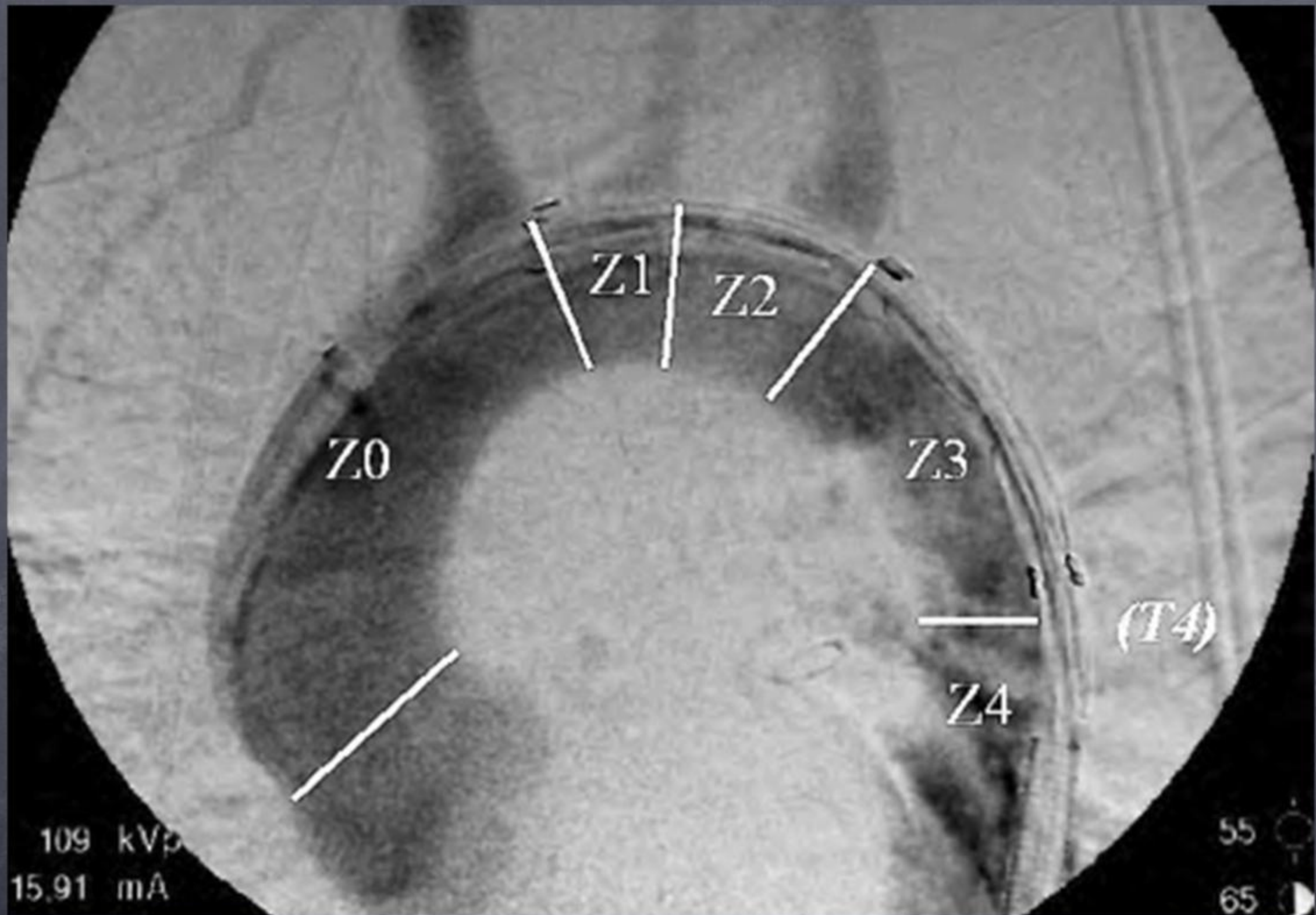




# BTAI Open repair.

- Death 20 -30%
- Paralysis 5% ( rates up to 20% reported with clamp and sew)
- Open thoracotomy - acute and chronic pain syndromes.







# Endovascular Stent Grafts for Acute Blunt Aortic Injury

M. B. Dunham, MD, David Zygun, MD, FRCP(C), P. Petrasek, MD, FRCS(C),  
John B. Kortbeek, MD, FRCS(C), Riyad Karmy-Jones, MD, FRCS(C), FACS, and  
Randy D. Moore, MD, FRCS(C)

June 2004

- Retrospective review, Jan 99 - Feb 00
- 28 patients with BTAI treated with EVSG
- 12 were delayed > 30 days
- 16 were acute F/U mean 11 months (3-30)
- 1 death, no graft complications, no paraplegia, 1 stroke due to co-existent carotid dissection.





# BTAI

- Parmley
  - Non operative management
  - Delayed operative management



# BTAI

## Delayed operation

- Significant CHI
- Severe ALI
- Multiple complex abdominal injuries with coagulopathy.
  - Risk of death in this group > 20%
  - Risk of delayed rupture before repair approx 5%



# BTAI

## No operation

- Minimal aortic injuries with intimal flap < 1cm and minimal periaortic hematoma.
- Small injury extending proximally into arch
- Severe cardiac / age related co-morbidity and/or severe atherosclerotic disease of the aorta.
- > 33% mortality/ 0% attributable to rupture.



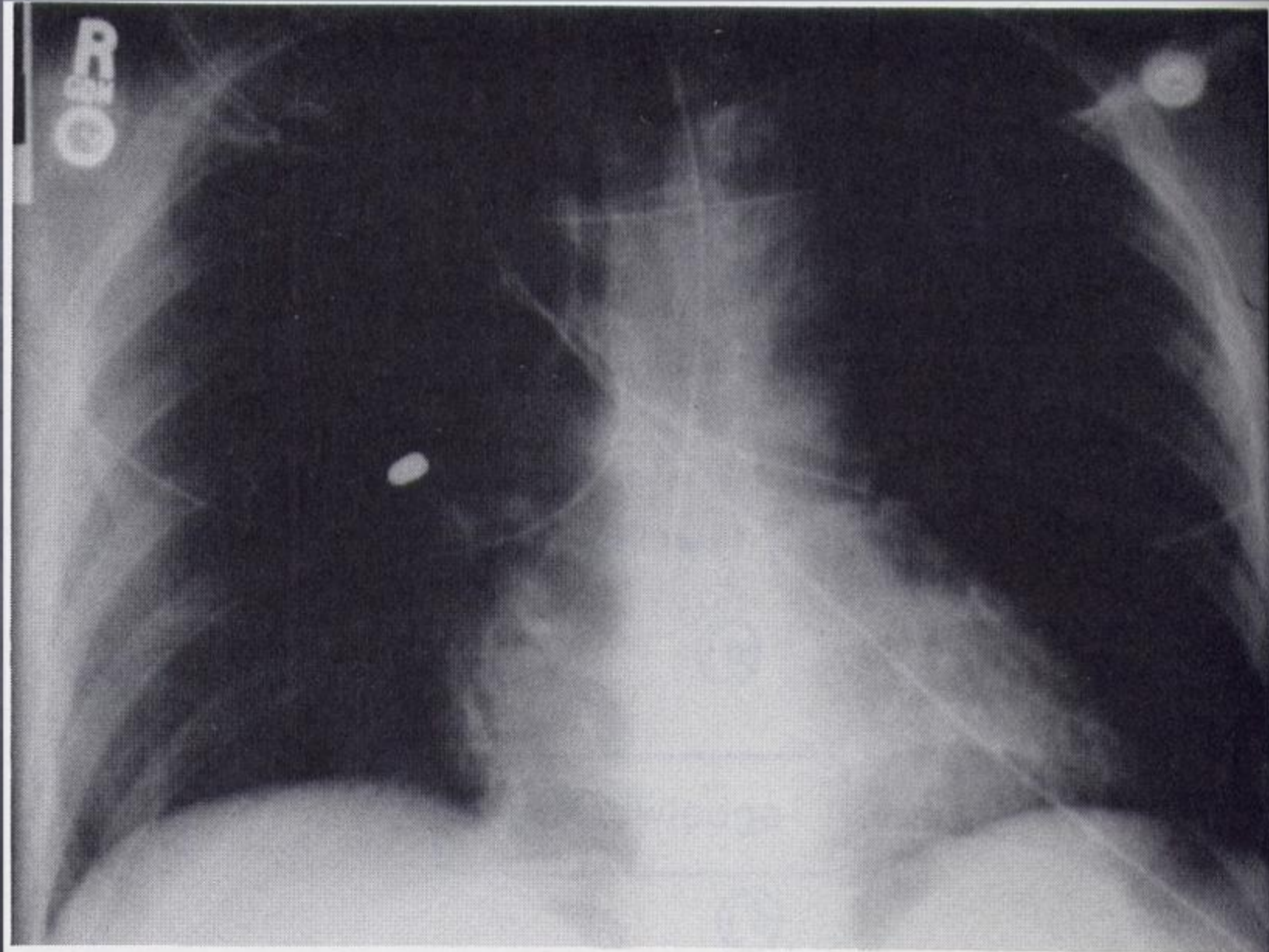


John Lennon, signing his life away, stops to give an autograph to Accused Killer Mark David Chapman

PAUL GORESH © 1980 NEW YORK NEWS INC.



# Case of the wandering bullet



**Figure 1.** Bullet seen in the midzone of the right chest adjacent to the hilum of the right lung.



# CONSERVATIVE MANAGEMENT OF A PULMONARY ARTERY BULLET EMBOLISM: CASE REPORT AND REVIEW OF THE LITERATURE

John B. Kortbeek, MD,<sup>a</sup> J. Allen Clark, MD,<sup>b</sup> and Robert C. Carraway, MD, FACS<sup>c</sup>





# Pulmonary Bullet emboli

- 32 cases - 3 (9% - Rx ?)
- 12 ( 30%) Thoracotomy for extraction.
- 3 (9%) percutaneous extraction
- 14 ( 44%) observation. F/U 9months - 5 years - No deaths or complications.





# Emergency & Resuscitative Thoracotomy

- Thoracotomies were classified as "emergent" when the procedure was performed for a patient in the Emergency Department (ED) or in the first 24 h after admission in the Operating Room (OR).
- Exclusion criteria: thoracotomies were not performed control of acute hemorrhage.





# Bullet emboli

- Pitfalls
- Removal
  - L sided cardiac
  - Large arterial
  - Right sided larger irregular projectiles
  - Mobile R intracardiac



# Bullet emboli

- Leave
  - Asymptomatic Pulmonary emboli
  - Immobile cardiac ( embedded, blurred)
  - Multiple small pellets.



# Bullet emboli

- Consider:
  - Bullets which have traversed GI tract
  - retained explosives
    - Devastator bullets
    - RPGs



# Conclusions

- 1. Indications for resus thoracotomy.
- 2. Stable juxtacardiac wounds non-op
- 3. Endovascular repair here to stay.
- 4. Missile emboli, look for it and beware the pitfalls






QuickTime™ and a  
DV/DVCPRO - NTSC decompressor  
are needed to see this picture.









# Chest Trauma Summary

1. ER Thoracotomy for Stab wounds with signs of life.
2. EVSG For BTAI, Select non-op
3. Juxtacardiac wounds, Always check the heart.
4. Beware the wandering bullet.



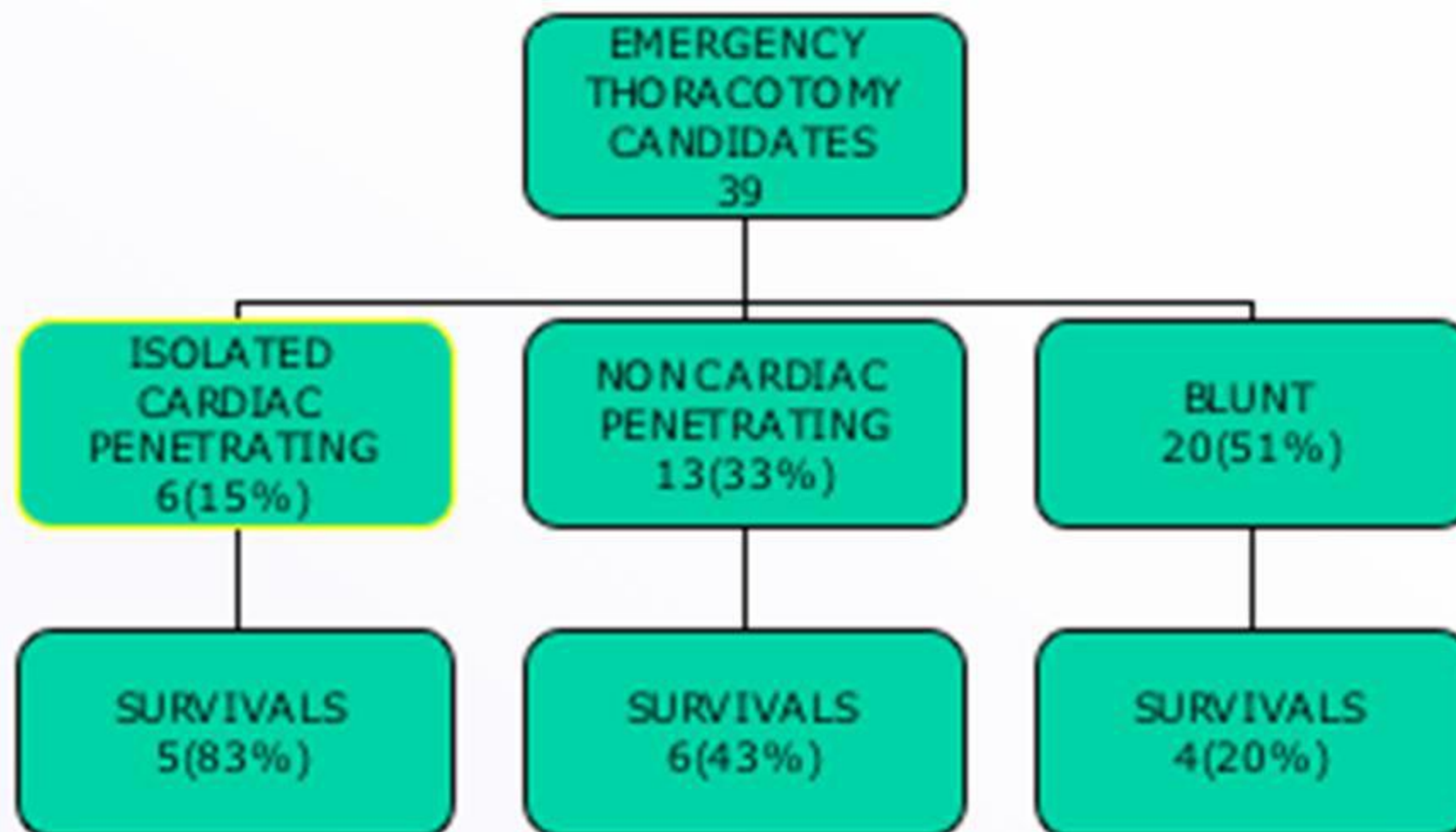


# Emergency & Resuscitative Thoracotomy

- Outcomes
- Survival rate.
- Comparison Mechanism of Injury and ER vs OR thoracotomy.  
Neurological status at discharge.









# Surgical Approach

